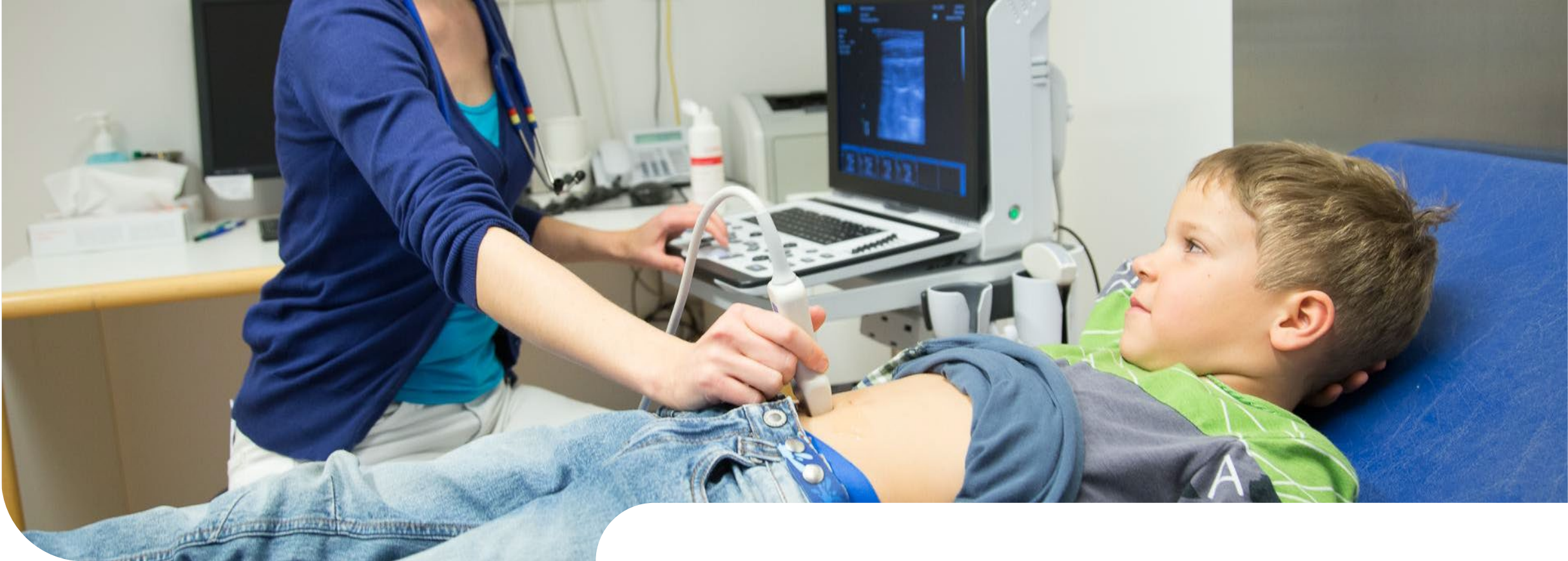



Ultrasound in continence

Diagnostic use and more



UMC Utrecht
Wilhelmina Kinderziekenhuis

Aart Klijn, Pediatric urologist

April 2025

Disclosures

I work as pediatric urologist in the UMC Utrecht and I have no disclosures

LUTS symptoms ?

At intake for urinary incontinence there is a screening for different causes of the LUTS symptoms (eg. Incontinence).

After intake/screening most patients start with urotherapy

not succesfull patients are referred to urology: a delay of 6 months up to 2 years

Can we improve first screening and shorten delay?

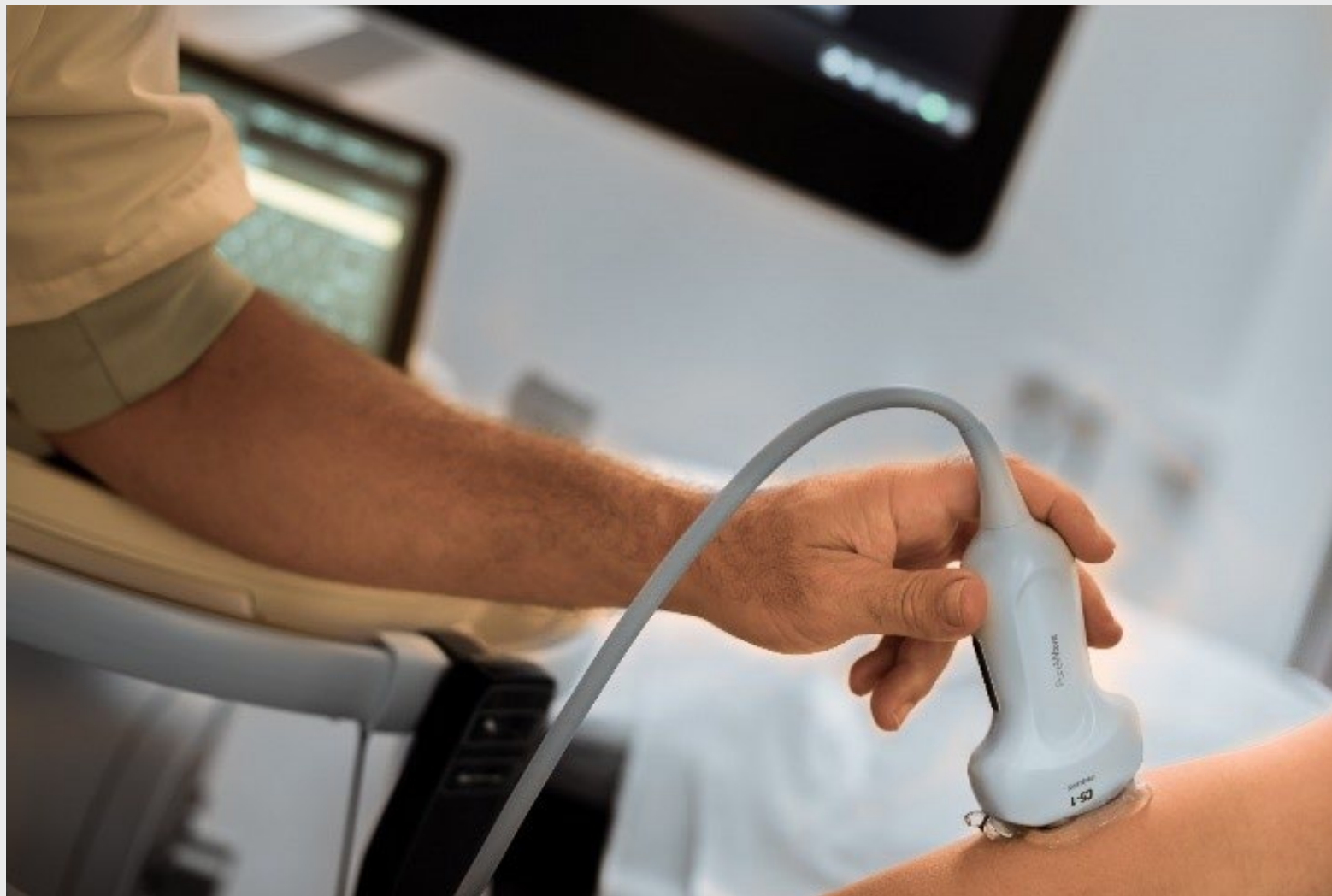And How?

Ultrasound

Diagnostical use for incontinence / LUTS intake,

Teaching / explaining parents and children the anatomy

Showing the action: Tool for biofeedback



US Diagnostics in LUTS

Kidney

double collecting systems / mega-ureter

Bladderwall:

diverticulum

Stone

tumor

ureterocele

Rectum

filling +/-

diameter

consistency of stool

Abd Renal
C5-1
42Hz
RS

TIS0.2 MI 1.3

2D
44%
Dyn R 48
P Low
HGen

M3

- 0

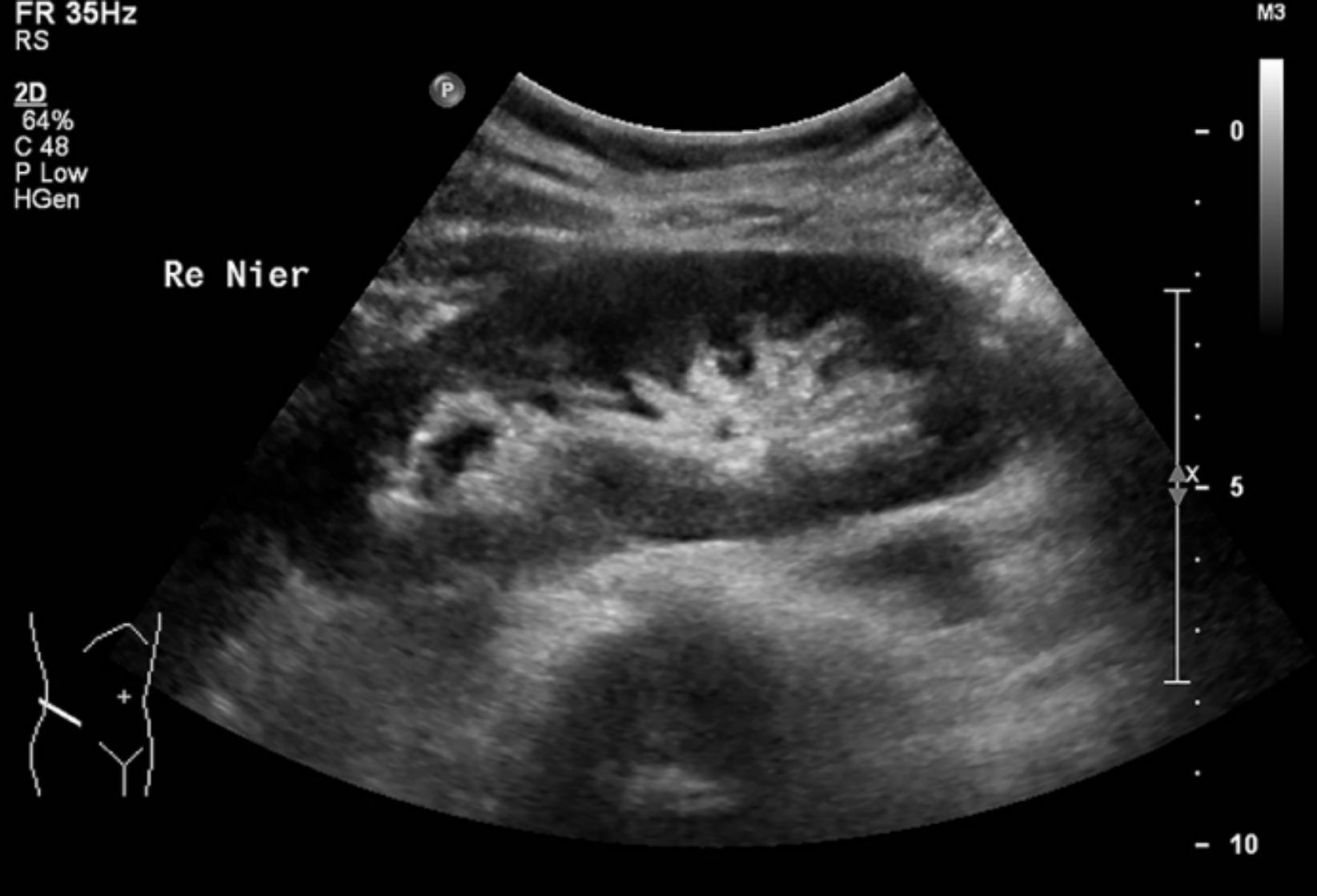- 5

- 10

x3

RT KIDNEY





US Diagnostics in LUTS

Kidney

double collecting systems / mega-ureter

Bladderwall:

diverticulum

Stone

tumor

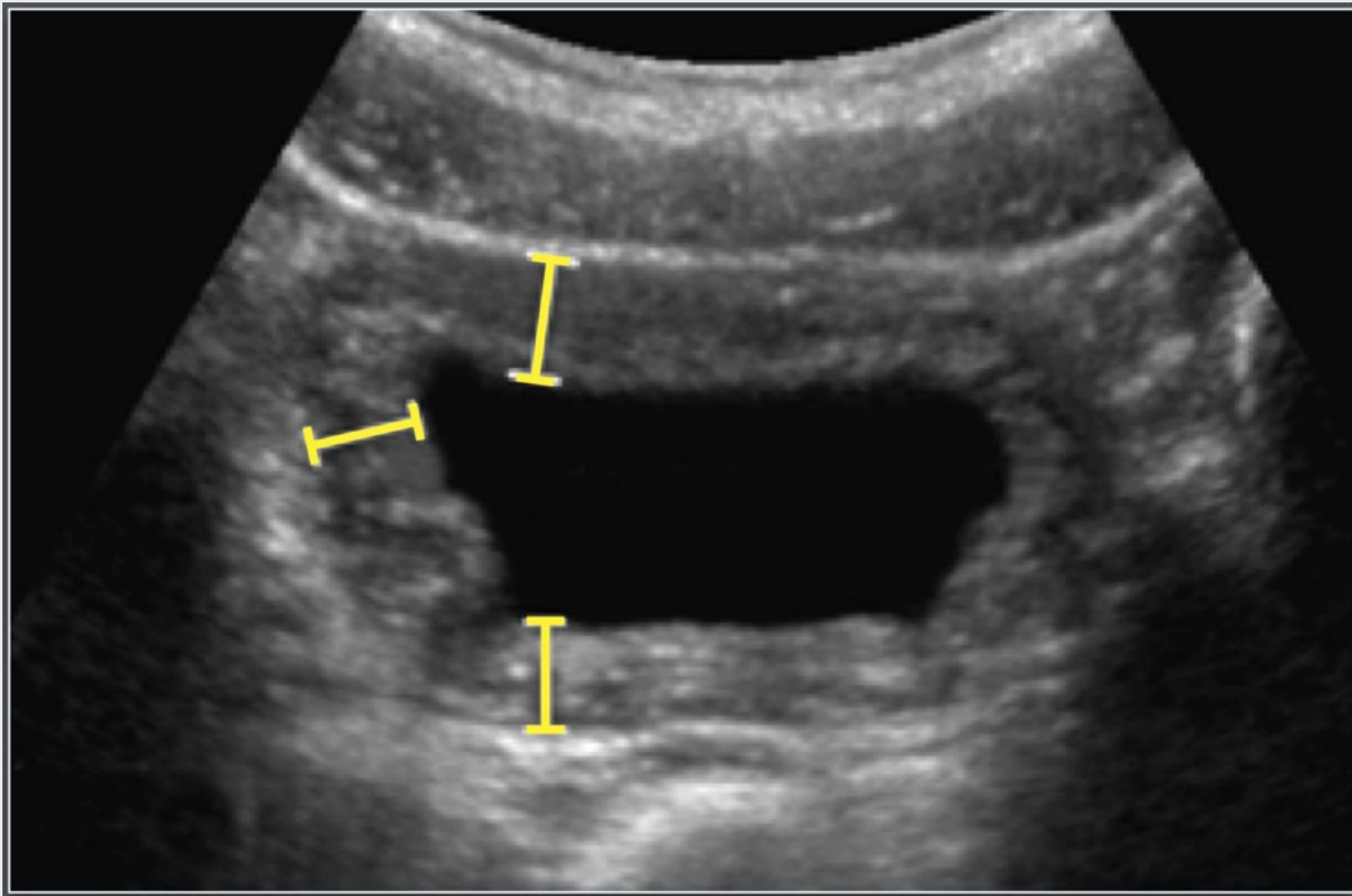
ureterocele

Rectum

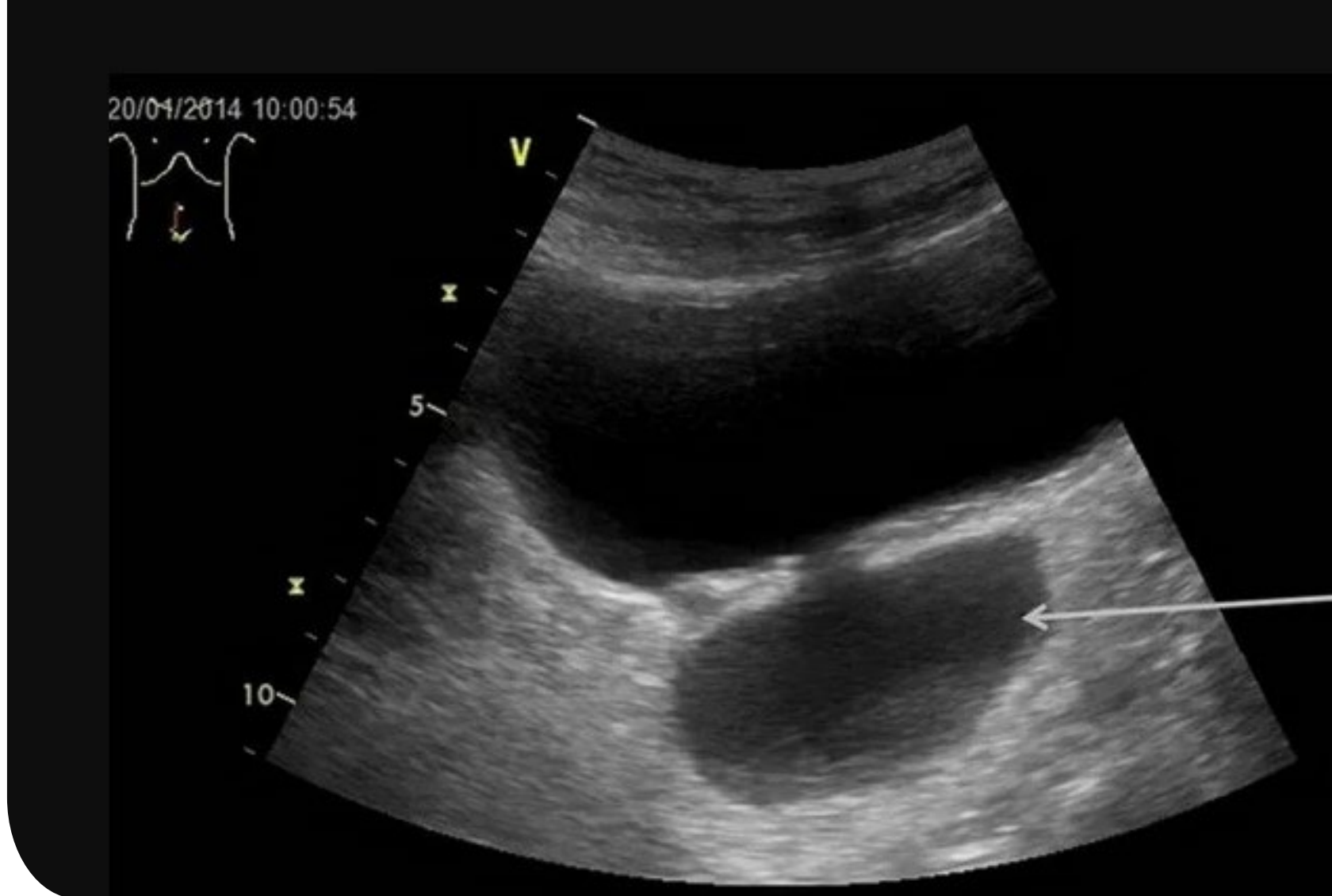
filling +/-

diameter

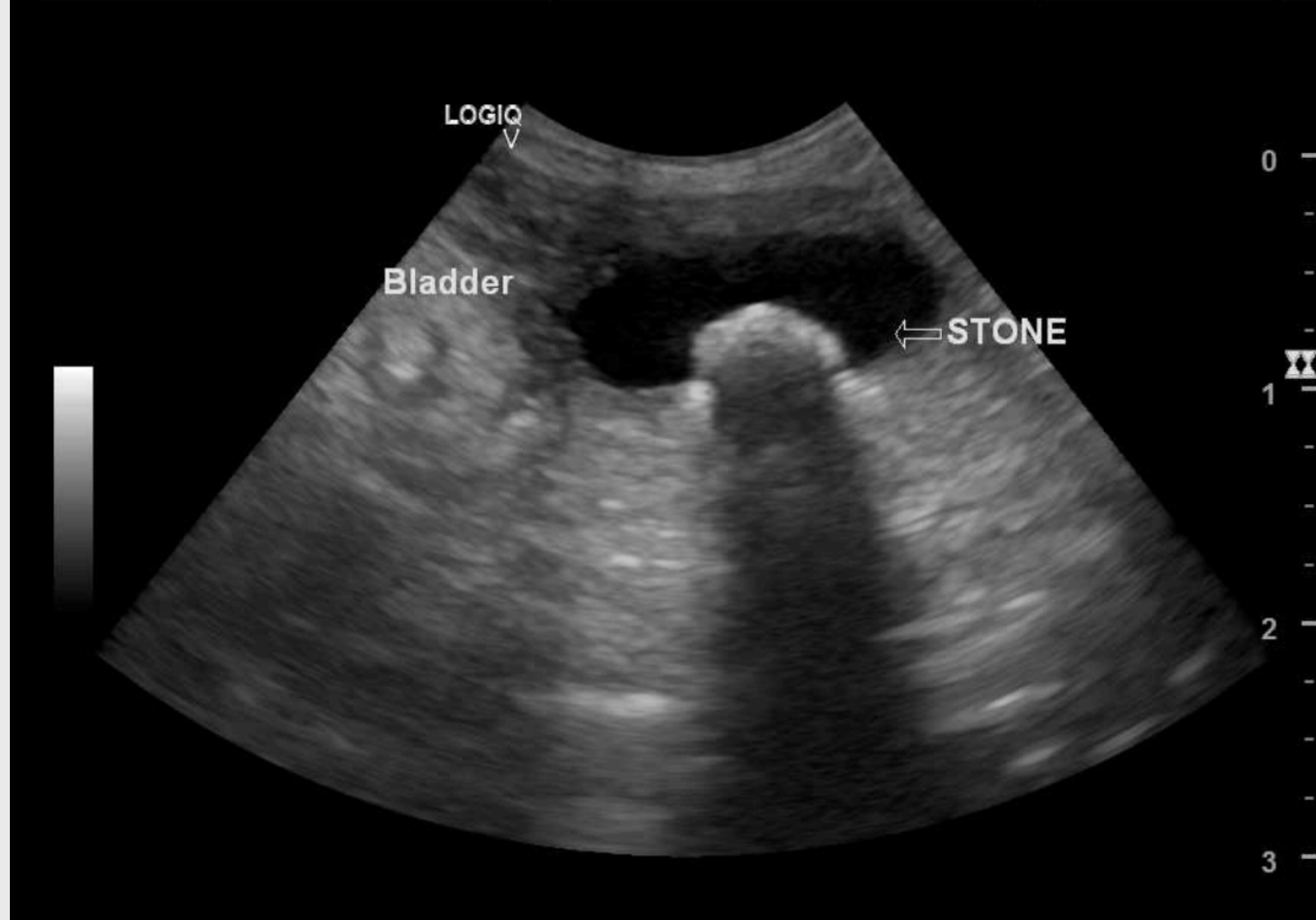consistency of stool



Thick bladderwall : OAB? obstruction? Large Volumes?

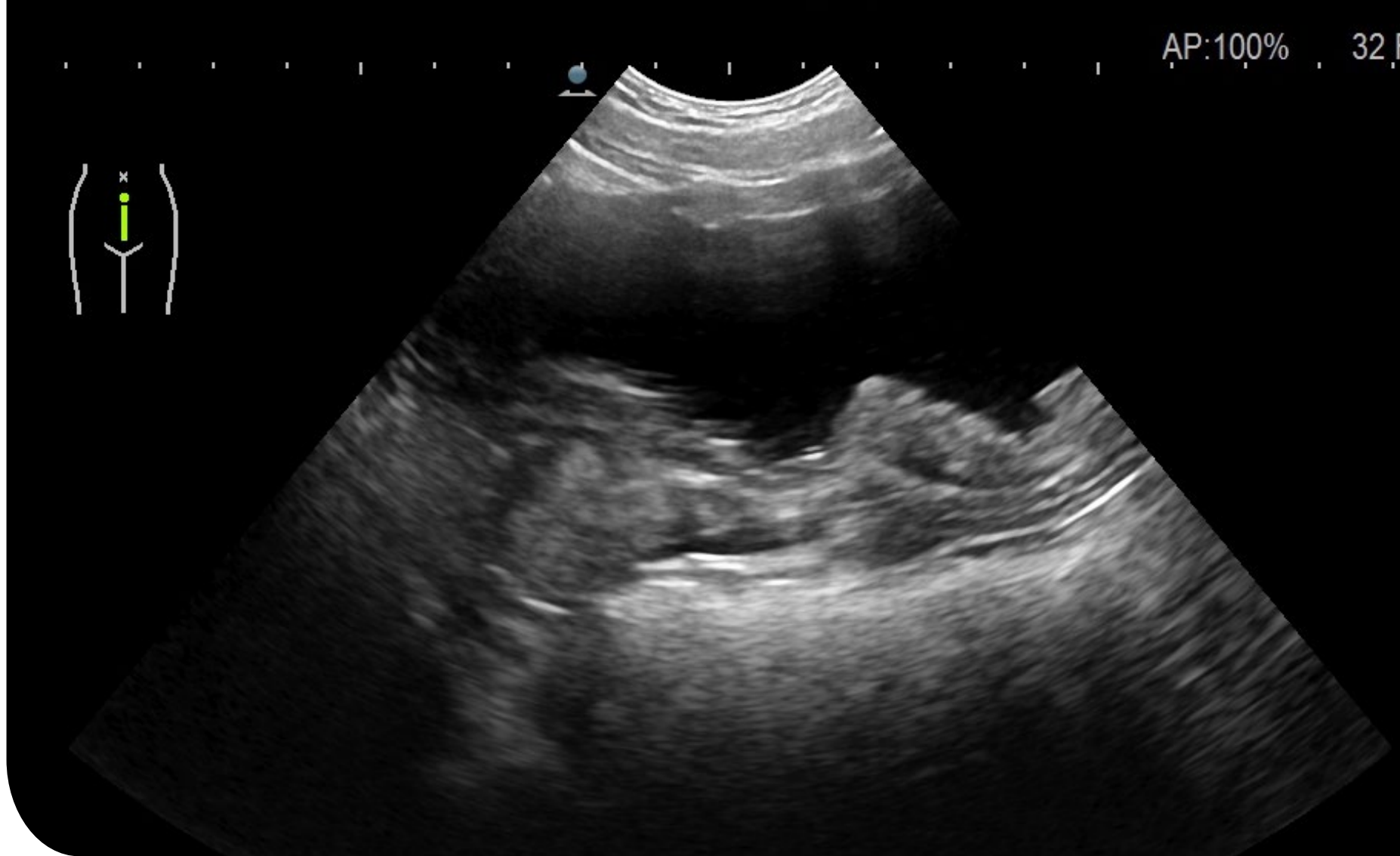


Diverticulum: chronic residu, infections, voiding pressures?

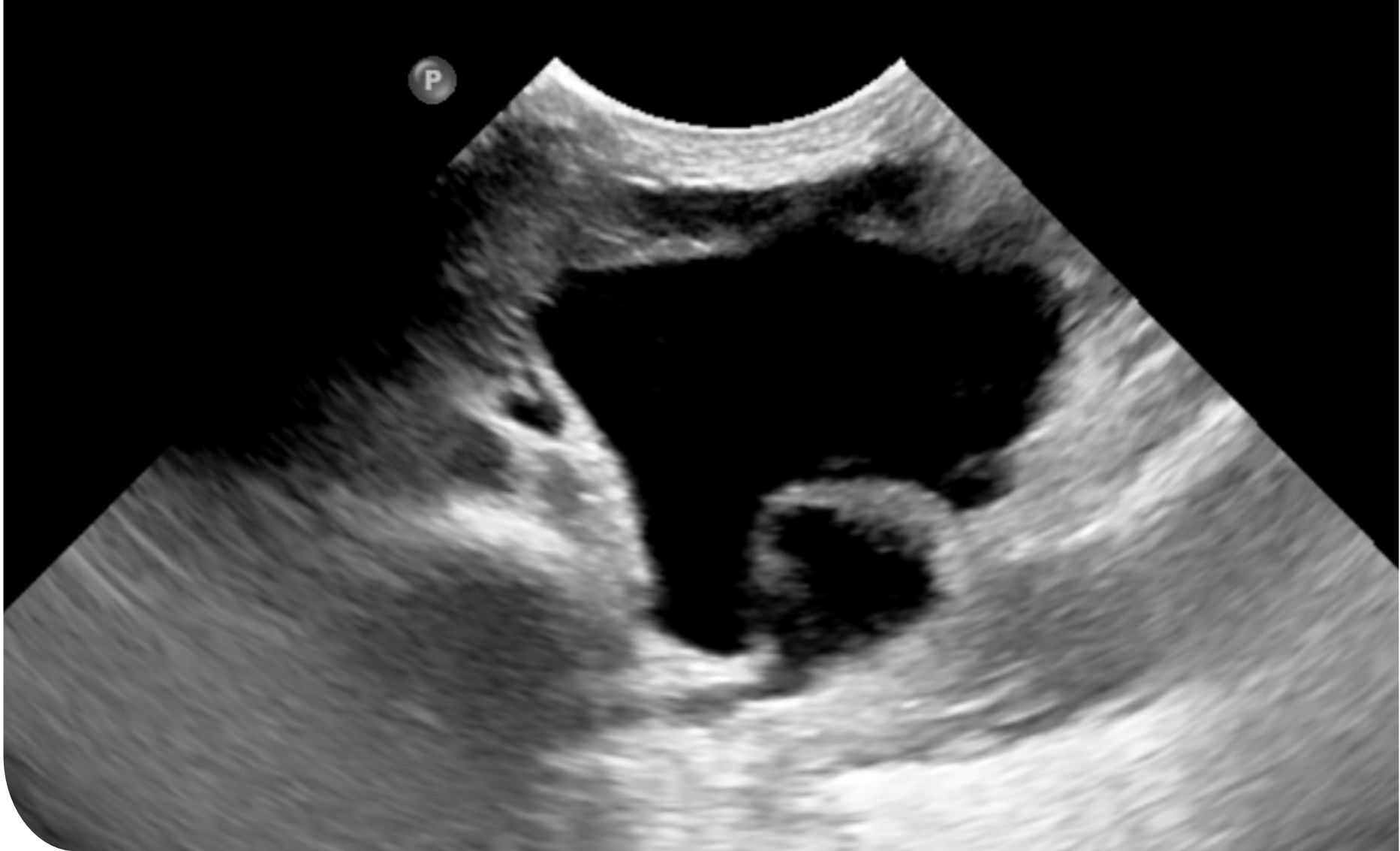

Stone: LUTS symptoms ++ , has many causes





Tumor: can give LUTS symptoms



Ureterocele: can give LUTS symptoms, mostly linked to double systems

US Diagnostics in LUTS

Kidney

double collecting systems / mega-ureter

Bladderwall:

diverticulum

Stone

tumor

ureterocele

Rectum

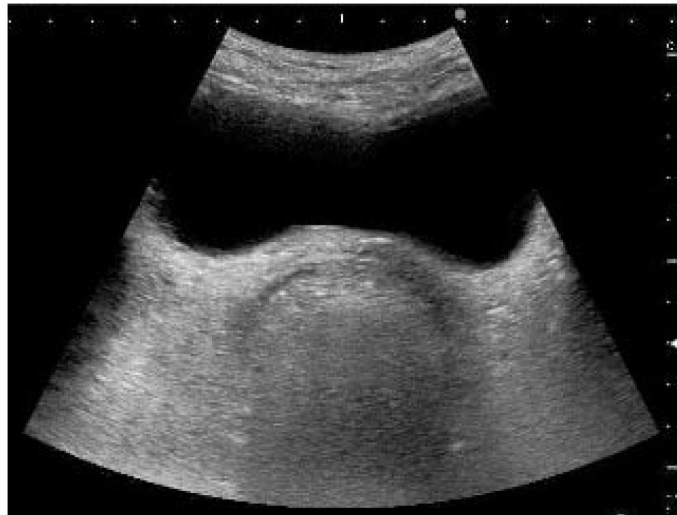
filling +/-

diameter

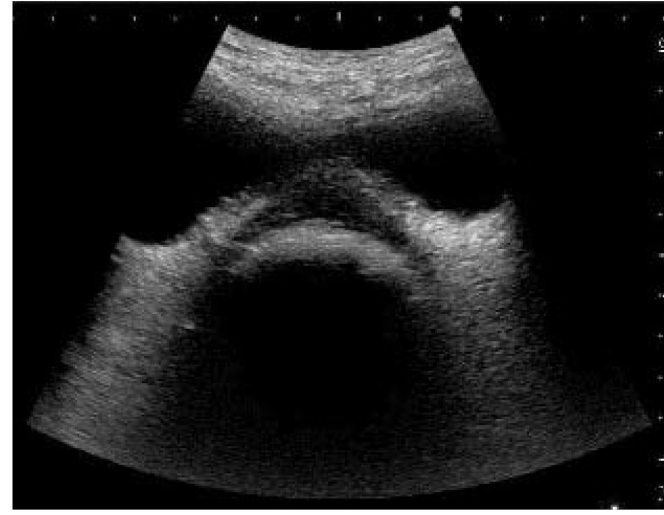consistency of stool



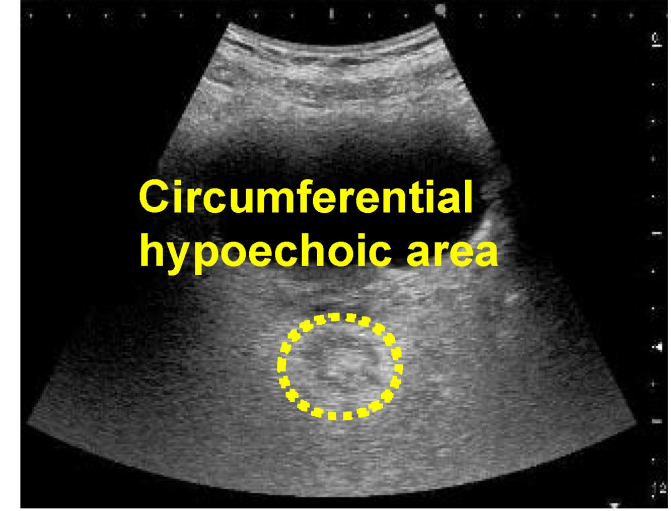
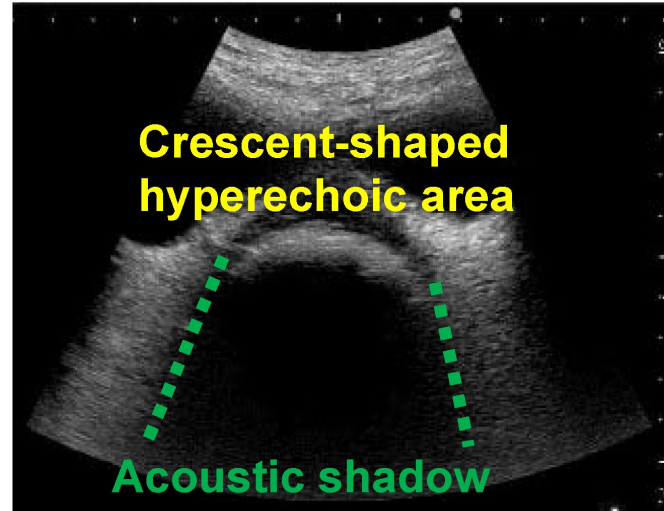
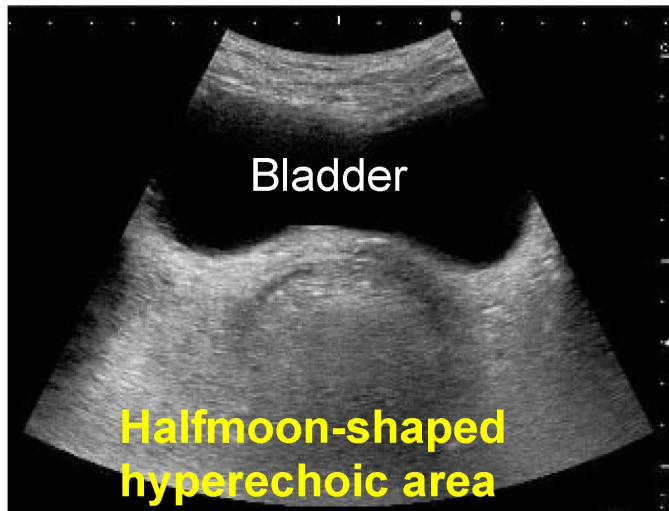
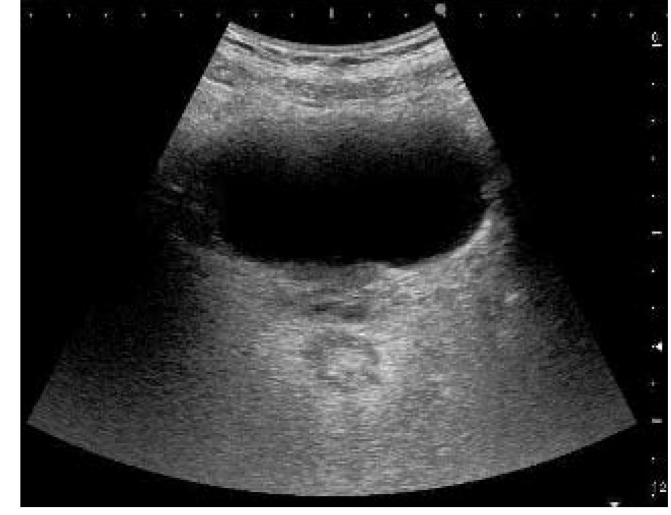A. Stool retention



B. Hard stool retention



C. No retention



US: Perineal view in sagittal images

On perineum or against the Vulva in a sagittal plane, lots of warm GEL

Urethra:

Length from bladder to pelvic floor

Direction of the stream?

bladderneck?: position / closed?

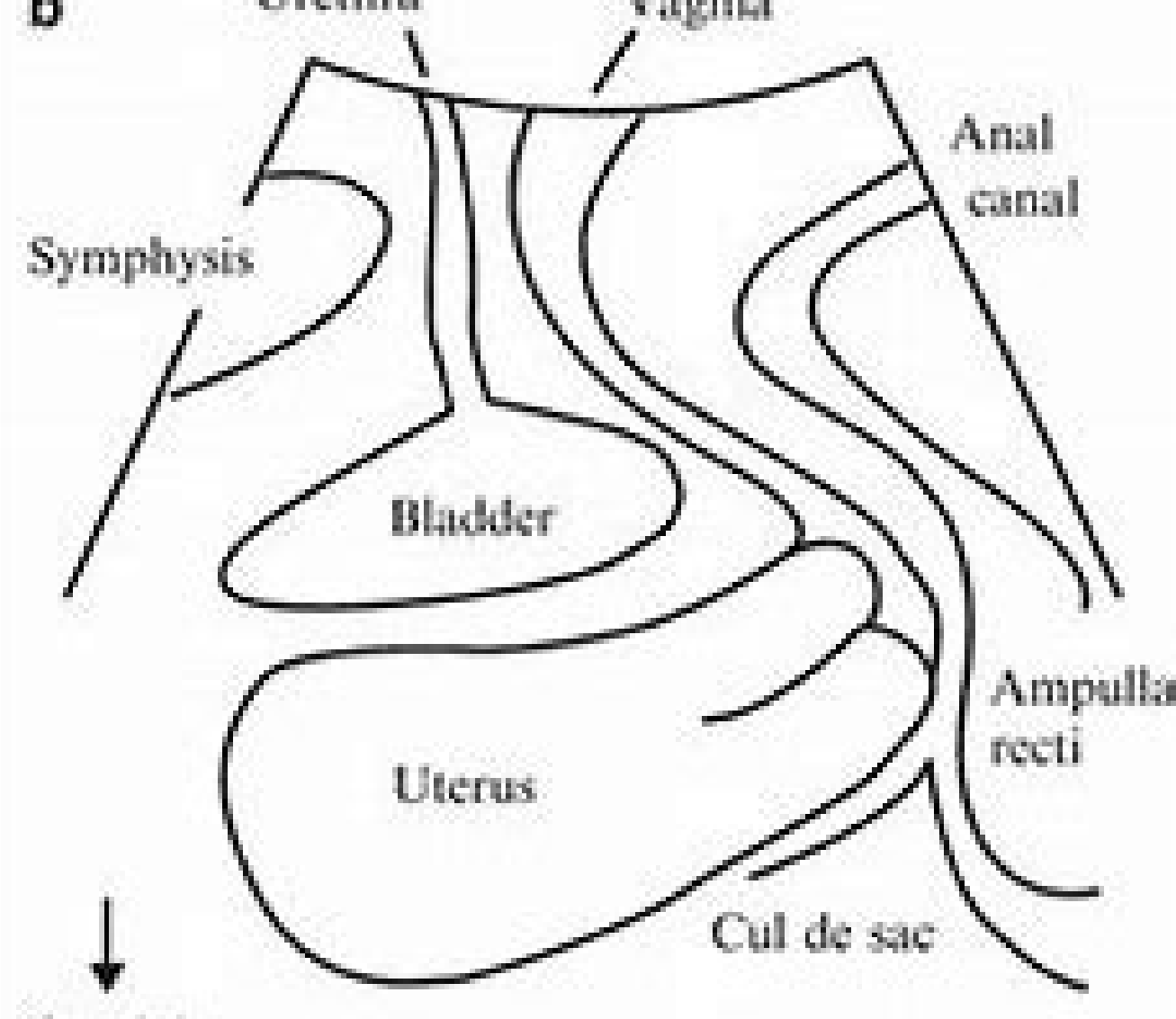
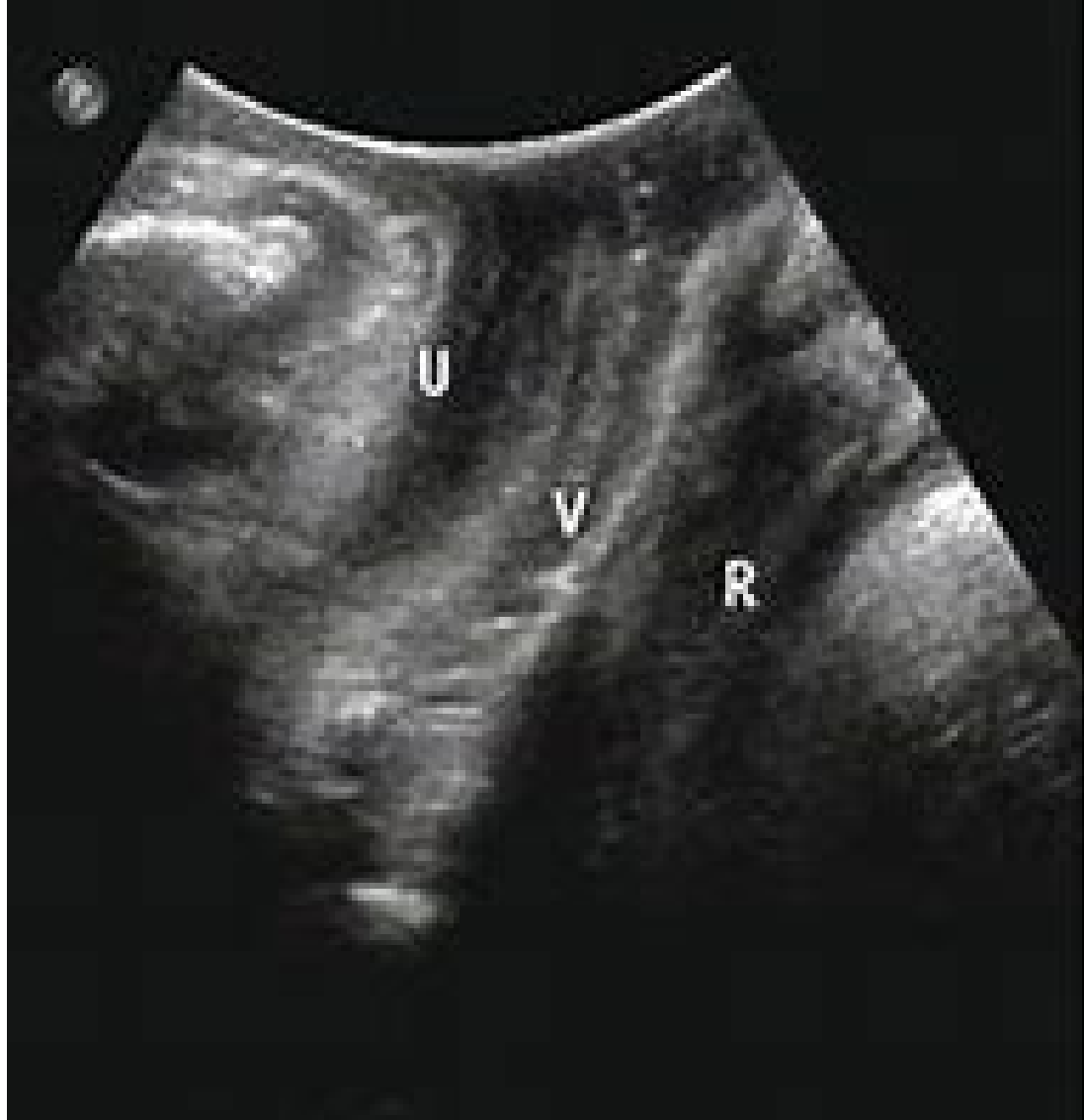
Other Pelvic views

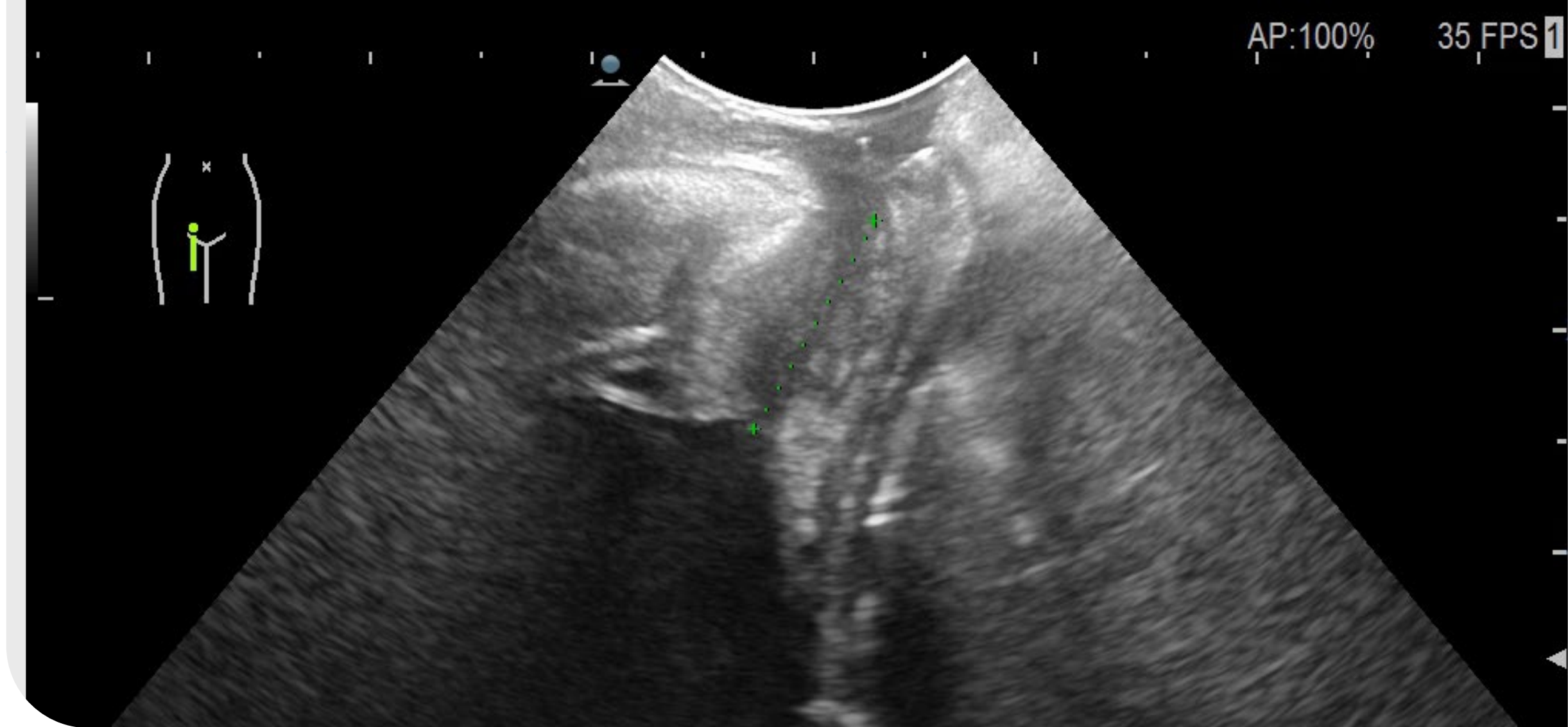
reflex of puborectalis:

cough

Straining/valsalva

Explain anatomy and functions in VIVO





US: What else?

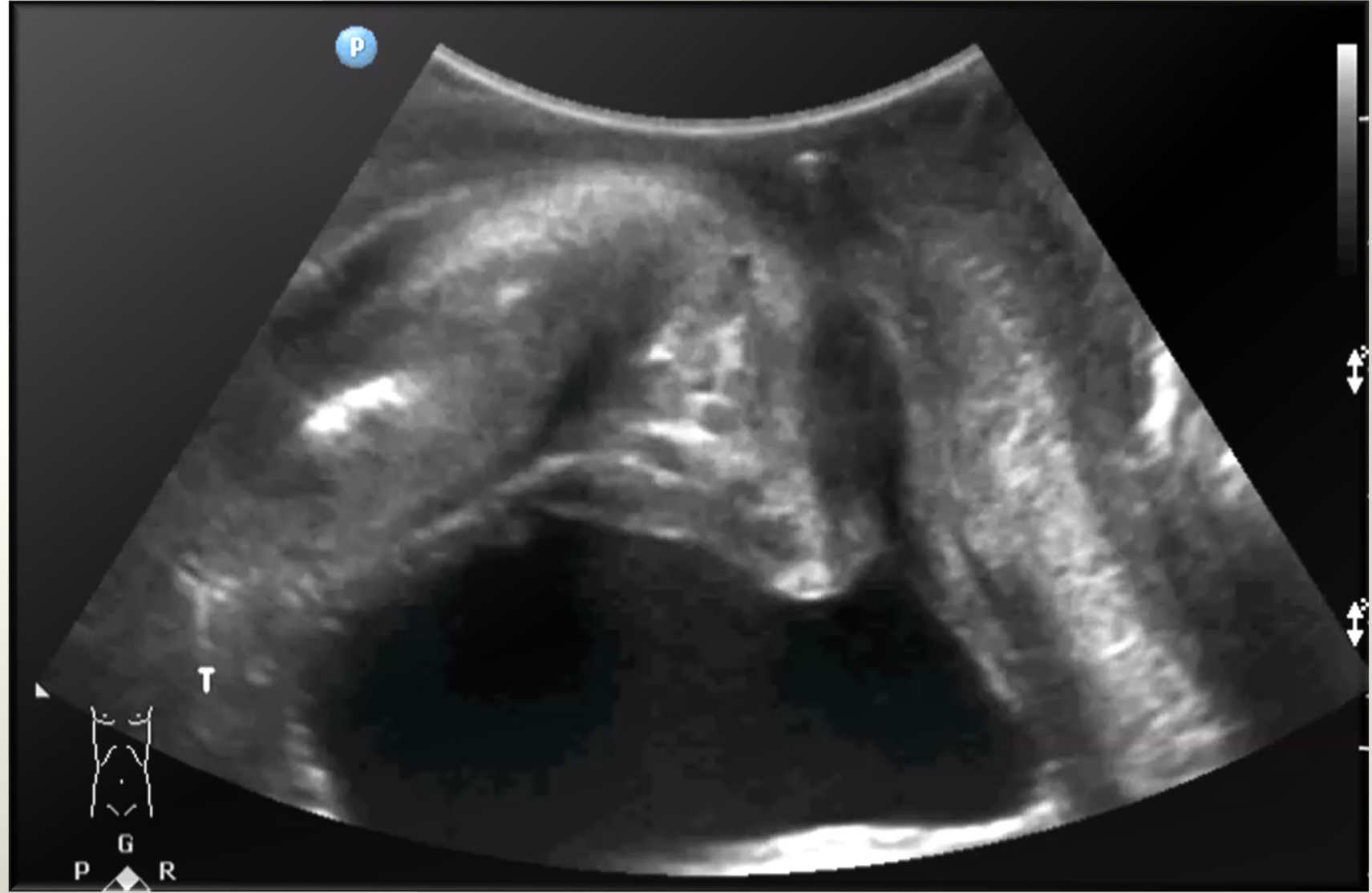Pelvic views
reflex of puborectalis:
cough
Straining/valsalva

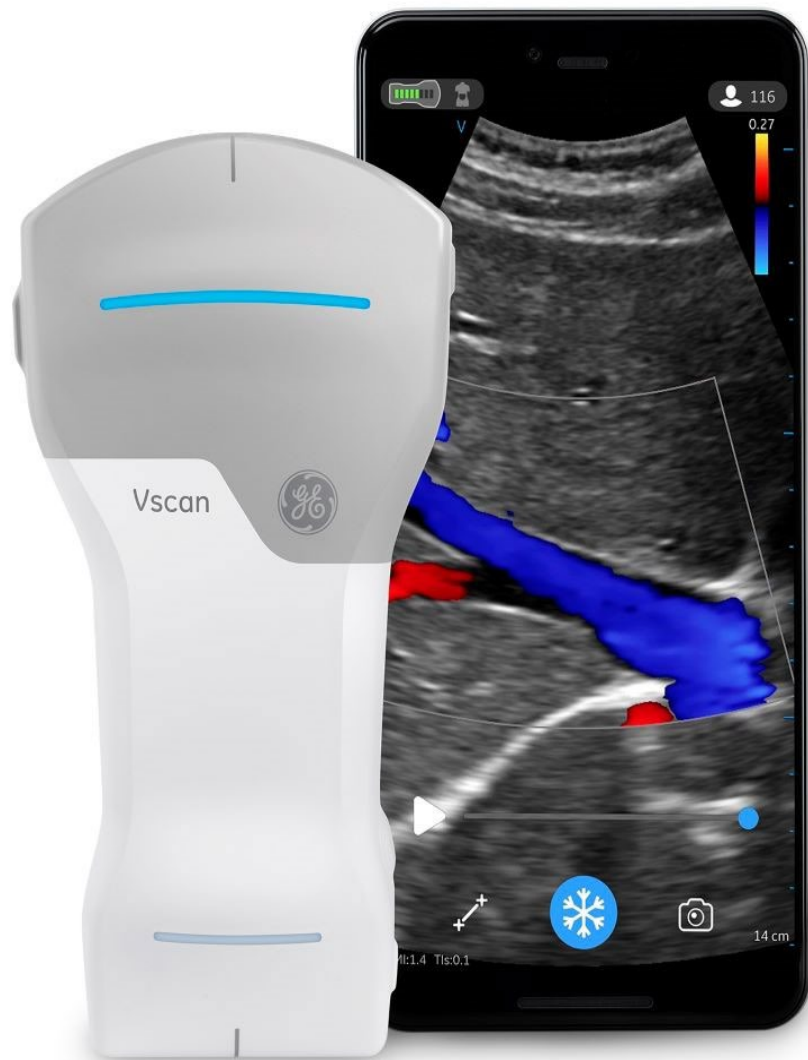Explain anatomy and functions in VIVO

Holding manouvre

(result of) Activation of pelvic floor muscles is a perfect option for teaching and biofeedback

Perineal or abdominal?





US: SPI? Tool for biofeedback

Sagital **P**erineal **I**maging

access for biofeedback (in selected patients)

feasibility ?

with a wireless ultrasound probe with an I-pad/Iphone as screen?

BUT:

First develop a protocol and proper evaluation for this **SPI TOOL**



UMC Utrecht

Wilhelmina Kinderziekenhuis